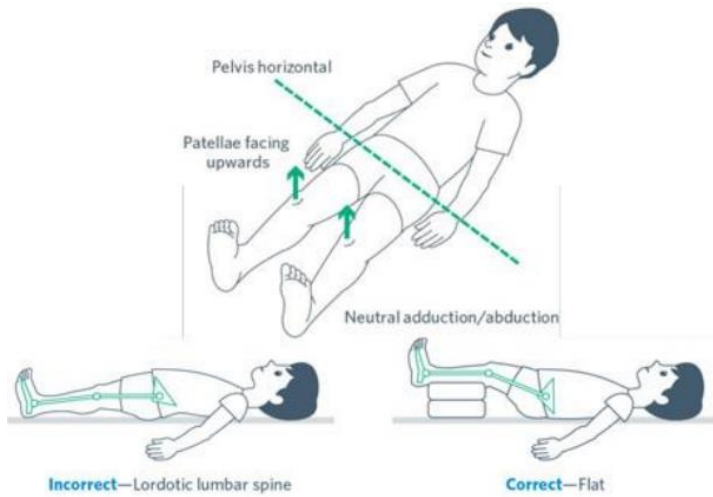
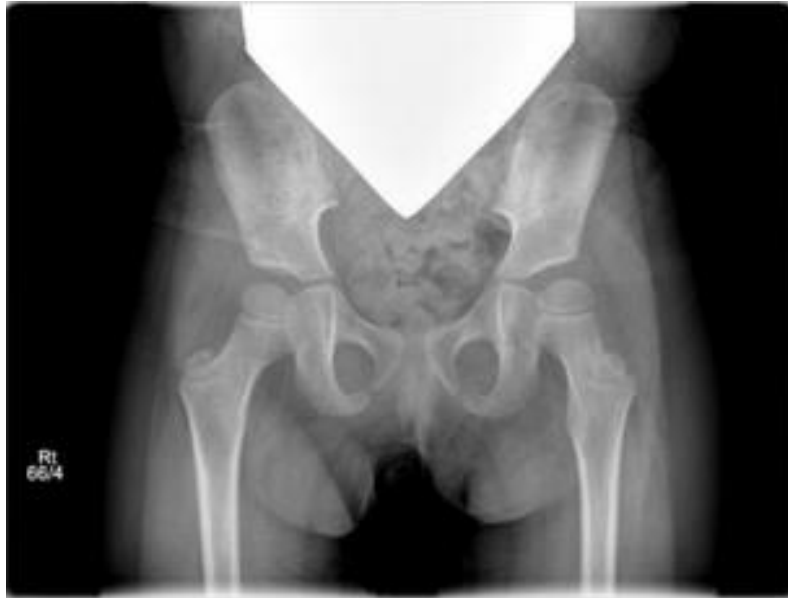

# Positioning for Hip Surveillance



<https://www.aacpdm.org/publications/care-pathways/hip-surveillance-in-cerebral-palsy>



Providers should indicate on the requisition that the radiographic exam is for hip surveillance.

## Anterior-posterior (AP) pelvis radiograph positioning:

- Supine
- Femurs in neutral adduction/abduction
- Position with neutral pelvic obliquity
- Flattened lumbar lordosis

## Field of view should include:

- Proximal femurs
- Visualization of iliac crest